



Lines, tubes, and devices

Abnormal nasogastric (NG) positioning

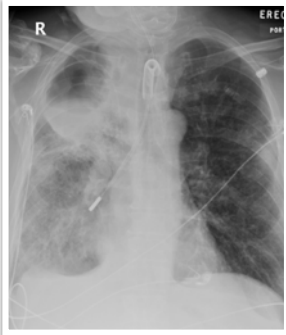What will I gain from this video?

After watching this video, you will know how to identify aberrantly positioned NG tubes.

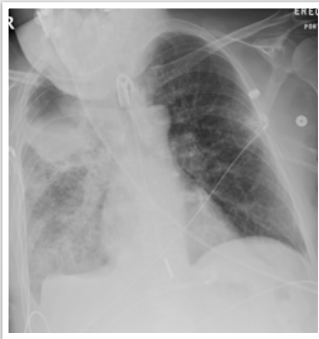
Complications of NG placement

- Too high—aspiration
- May be coiled
- Esophageal or gastric tears, perforation
- Placement in airways
- Intracranial placement

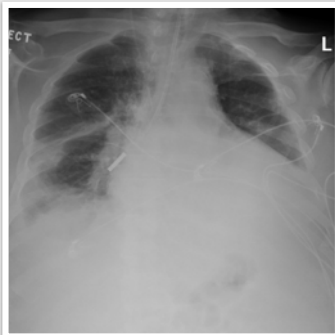
Case 1



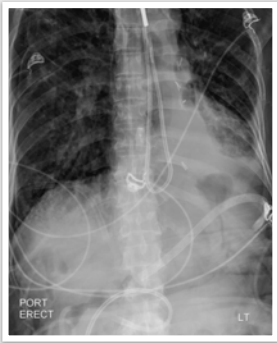Case 2



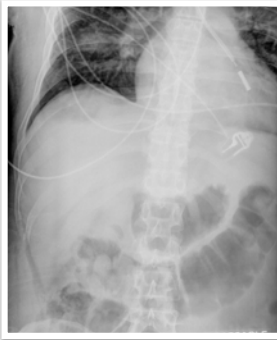
Case 3



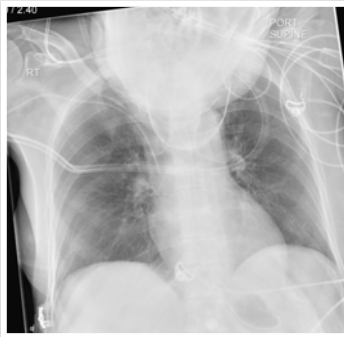Case 4



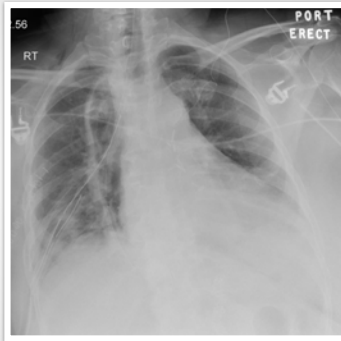
Case 5



Case 6



Case 7



For high-risk patients, use two-step approach to placement of Dobhoff tubes—insert tube to just past carina and X-ray. If OK, then advance safely.

Tubes can be positioned—too high in upper esophagus.

Tubes can be positioned in the lungs and even in the pleura.

Tubes can be coiled, kinked, and form knots.
